PART 12 | Genitourinary

CHAPTER
86 The testis and scrotum

Learning objectives

To diagnose and manage:
- Testicular maldescent
- Testicular torsion
- Common scrotal swellings (varicocele, hydrocele and epididymal cysts)
- Testicular and scrotal infections
- Testicular tumours
- Male factor infertility
- Testicular trauma

INCOMPLETE DESCENT OF THE TESTIS

Definition

Incomplete descent of the testis, also known as cryptorchidism, occurs when one or both testes are arrested at some point in the normal path to the scrotum. An ectopic testis is a testis that is abnormally placed outside this path (*Figure 86.1*).

Incidence

About 3% of full-term and 30% of premature male infants are born with one or both testes undescended. About two-thirds of these reach the scrotum during the first 3 months of life, but full descent after that is uncommon. The incidence of testicular maldescent at the age of 1 year is around 1%. The condition is sometimes missed in the neonatal period and only discovered later in life. The presence of a hernia, testicular pain or acute torsion may direct attention to the abnormality. Cryptorchidism occurs in approximately 1.5–4% of fathers and 6% of brothers of individuals with cryptorchidism.

Pathology

The condition is more common on the right and is bilateral in 20% of cases. In adults, secondary sexual characteristics are typically normal.

The testis may be:

- intra-abdominal; usually extraperitoneal just inside the internal inguinal ring;
- within the inguinal canal; it may not be palpable (*Figure 86.2*);
- extracanalicular; usually at the scrotal neck (high scrotal);

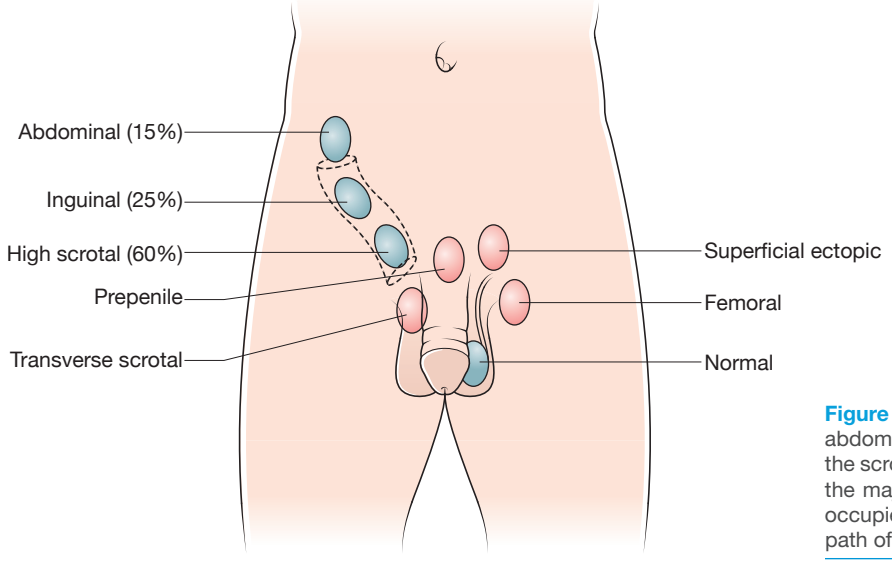

Figure 86.1 The path of descent of the testis from the abdomen (retroperitoneal) down the inguinal canal to the scrotum. Descent can be arrested at any stage with the majority in the high scrotal area. Rarely, the testis occupies a more ectopic position outside the normal path of descent (courtesy of Dr Mohan Gundeti).

Figure 86.2 Undescended testes in a boy aged 12 years. Note the bilateral undescended testes with the underdeveloped scrotum. In cases of retractile testis, the scrotum is relatively well developed.

- ectopic; an ectopic testis is one that has ended up away from the normal path of descent. The commonest site is the superficial inguinal pouch, just inferior and medial to the superficial inguinal ring. Other rarer ectopic sites include the femoral triangle, root of the penis and perineum.

Incompletely descended testes are often macroscopically normal in early childhood, but by puberty the testis is typically smaller than its intrascrotal counterpart. Microscopic changes are apparent from 1–2 years, including loss of Leydig cells, degeneration of Sertoli cells and decreased spermatogenesis. The higher the testis, the greater the degree of histological change.

Consequences

Infertility

Men with undescended testes may have reduced fertility, even after orchidopexy.

- The infertility rate for unilateral cases is not believed to be very different from the general population.
- The fertility reduction after orchidopexy for bilateral cryptorchidism is about 38%.
- Patients with bilateral undescended testes who receive orchidopexies as adults are almost always infertile and azoospermic; but there are reports of pregnancies achieved through sperm retrieval and assisted reproduction in this group.
- The recommendation for early surgery is due to degeneration of spermatogenic tissue and reduced spermatogonia counts after the second year of life in patients with untreated undescended testes.

Malignancy

Overall, the risk of testicular cancer if orchidopexy is done before puberty is around two to three times that of the general population. It is five to six times higher when orchidopexy is done after puberty. The risk of cancer does not seem to be different when orchidopexy is done early in infancy compared with later in childhood.

- The most common type of testicular cancer in untreated undescended testes is seminoma.
- The peak age range for this tumour is 15–45 years.
- In contrast, after orchidopexy, seminomas represent only 30% of testicular tumours in previously undescended testes.
- It is treatable if caught early, so boys who had an orchidopexy as infants should be taught testicular self-examination.

Hernia

Around 90% of boys with an undescended testis have a patent processus vaginalis although the incidence of a clinically apparent hernia is much lower.

Testicular torsion

The undescended testis is more prone to testicular torsion, largely as a consequence of a developmental abnormality between the testis and its mesentery.

Summary box 86.1

Undescended testis

- Testes that are absent from the scrotum after 3 months of age are unlikely to descend
- Histological changes in the testis can be seen from 1 year of age
- An incompletely descended testis tends to atrophy as puberty approaches
- Boys with undescended testes are at greater risk of infertility, testicular malignancy, hernia and torsion

Clinical features

When assessing a child with suspected testicular maldescent, it is helpful to have the boy as relaxed as possible in a warm room, usually in a supine position. The important differential diagnosis is the so-called 'retractile testis'. During childhood the testes are mobile and the cremasteric reflex is active, so that, in some boys, any stimulation of the skin of the scrotum or thigh causes the testis to ascend and to temporarily disappear into the inguinal canal. When the cremaster relaxes, the testis reappears only to vanish when the scrotal skin is touched again.

In comparison with a true undescended testis, the scrotum in the retractile testis is normal as opposed to underdeveloped, and the retractile testis can be gently milked from its position in the inguinal region to the bottom of the scrotum. A diagnosis of true incomplete descent should be made only if this is not possible. For retractile testes, a yearly physical examination is recommended because of the 2–50% reported risk of a retractile testis becoming an acquired undescended testis.

More than 70% of cryptorchid testes are palpable by physical examination. In the remaining 30% of cases with a non-palpable testis, the challenge is to confirm the absence or presence of the testis and to identify the location of the viable non-palpable testis. Ultrasound has a high positive predictive value for inguinal located testes, but only 45% sensitivity in

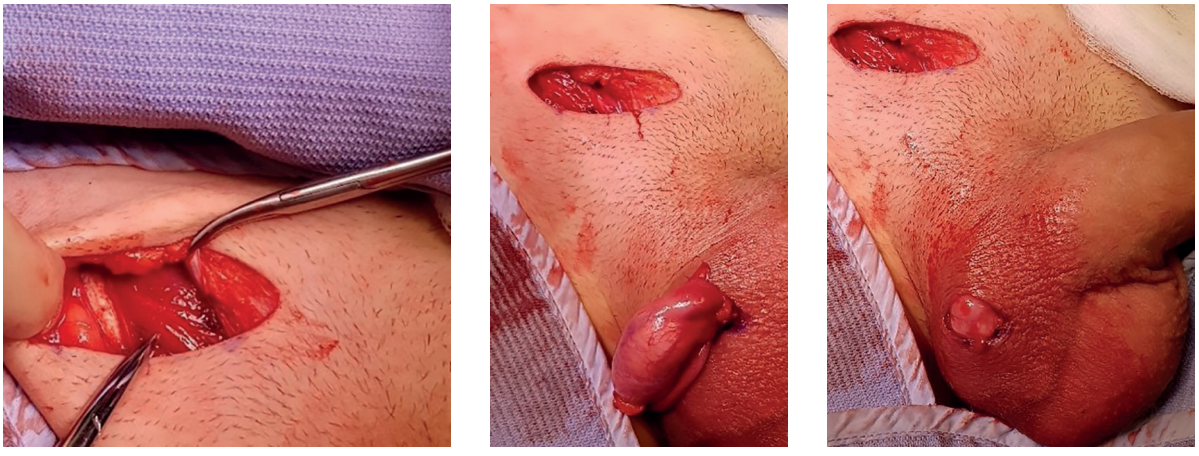

Figure 86.3 Adult undescended testis. The undescended inguinal testis is mobilised and retained in a pouch constructed between the dartos muscle and skin (courtesy of the author and Dr Mohamed Abdellatif).

localising all non-palpable testes. The cost and ionising radiation exposure associated with computed tomography (CT) scanning preclude its use. Magnetic resonance imaging (MRI) has been more widely used with greater sensitivity and specificity but has cost and availability issues, and may require anaesthesia in the paediatric population. At this time, there is no radiological test that can conclude with 100% accuracy that a testis is absent. Instead, laparoscopy has become the gold standard diagnostic method for a non-palpable testis. In addition, laparoscopy provides an option for treatment of this condition.

Summary box 86.2

Retractile testis

- Retractile testes should be differentiated from true undescended testes
- This is most easily done with the child relaxed in a warm room
- Retractile testes are more common than true undescended testes
- Retractile testes require no treatment but should be monitored

Medical treatment

There is little evidence currently for hormonal therapy to induce testicular descent, with low response rates (equivalent to placebo) and a lack of long-term efficacy.

Surgical treatment

Orchidopexy

Orchidopexy is usually performed between 6 and 18 months of age in an attempt to prevent the consequences described earlier. For premature babies, corrected age is used to determine surgery timing. The testis and spermatic cord are mobilised and the testis is repositioned in the scrotum. The operation is performed through a short incision over the deep inguinal ring. The inguinal canal is exposed by division of the external oblique aponeurosis in the direction of its fibres.

Three manoeuvres help to gain the length required to bring the testis down into the bottom of the scrotum. First, the patent processus vaginalis should be identified, separated and ligated. Second, the coverings of the spermatic cord (including the cremasteric muscle) should be divided and, third, lateral fibrous bands just inside the internal inguinal ring should be divided. Although these techniques are usually effective, the tiny vas and testicular vessels are vulnerable to injury. The empty hemiscrotum is stretched with a finger passed into it through the inguinal incision to give enough room for the testis, which is placed in a pouch constructed between the dartos muscle and the skin (***Figure 86.3***).

Orchidectomy should be considered if the incompletely descended testis is atrophic and/or there is a suspicion of malignancy, particularly in the postpubertal boy if the other testis is normal.

Impalpable testis

For non-palpable testes under anaesthesia, diagnostic laparoscopy is recommended. If a testis is found during laparoscopy, the options are:

1. Laparoscopic orchidopexy preserving the vessels: the testis is dissected off a triangular pedicle containing the testicular vessels and the vas.
2. Laparoscopic one-stage Fowler–Stephens orchidopexy: vessels are divided and the testis is dissected off a pedicle of the vas and brought down in one stage.
3. Laparoscopic two-stage Fowler–Stephens orchidopexy: vessels are divided with clips but dissection of the testis is postponed for 6 months to allow for optimal development of collaterals.

Robert Fowler Jr, b. 1928, paediatric surgeon, Royal Children's Hospital, Melbourne, Australia.
Frank Douglas Stephens, 1913–2011, paediatric surgeon, Royal Children's Hospital, Melbourne, Australia, published a landmark paper with Robert Fowler in 1959 that described the surgical management of high undescended testes by dividing the testicular vessels high from the testis to maintain a collateral blood supply.

If no testis is found during exploratory laparoscopy, one has to determine the presence of either blind-ending vessels or a testicular nubbin to completely rule out a missing testis. The vas can be dissociated from the testis and thus is not always a good guide to find the gonad.

If the internal ring is closed but vessels are going into it, a scrotal exploration usually will find a testicular nubbin. If vessels are going into an open inguinal ring, one can usually push the testis into the abdomen; if not, an inguinal or scrotal exploration would be warranted.

Absent testis

'Vanishing' testis describes a condition in which a testis develops but disappears before birth. The most likely cause for this is prenatal torsion. True agenesis of the testis is rarer. Laparoscopy is useful in distinguishing these causes of clinically absent testis from intra-abdominal maldescent.

TORSION OF THE TESTIS

Definition

Testicular torsion is the twisting of the spermatic cord and its contents such that the testicular blood supply becomes compromised. If left untreated the blood flow to the testicle ceases and the testicle dies. Testicular torsion is therefore a surgical emergency and the earlier the surgery to untwist the testis can be undertaken the better the outcome.

Incidence

Testicular torsion affects 3.8 per 100 000 males younger than 18 years annually. It accounts for 10–15% of acute scrotal disease in children.

Pathophysiology

Torsion of the testis is uncommon because the normal testis is anchored and cannot rotate. Extravaginal torsion is seen almost exclusively in neonates because of the increased mobility of the testicle before the descent into the scrotum when attached to the scrotal wall via the tunica vaginalis. Beyond this age, intravaginal torsion occurs as a result of a combination of:

- High investment of the tunica vaginalis, causing the testis to hang within the tunica like a clapper in a bell (*Figure 86.4*). This is the most common cause in adolescents and is typically a bilateral abnormality.
- Inversion of the testis: the testis is rotated so that it lies transversely or upside down.
- Separation of the epididymis from the body of the testis, permitting torsion of the testis on the pedicle that connects the testis with the epididymis (*Figure 86.4*).

Normally, when there is a contraction of the abdominal muscles, the cremaster contracts as well. In the presence of one of the abnormalities described above, the spiral attachment of the cremaster favours rotation of the testis around the vertical axis. Sudden contraction of the cremasteric muscle, which may be a response to mechanical, sexual or thermic stimulation, may cause a rotational effect on the testis as it is pulled upward. Accordingly, straining at stool, lifting of a heavy weight, sexual activity and sport can all precipitate an episode.

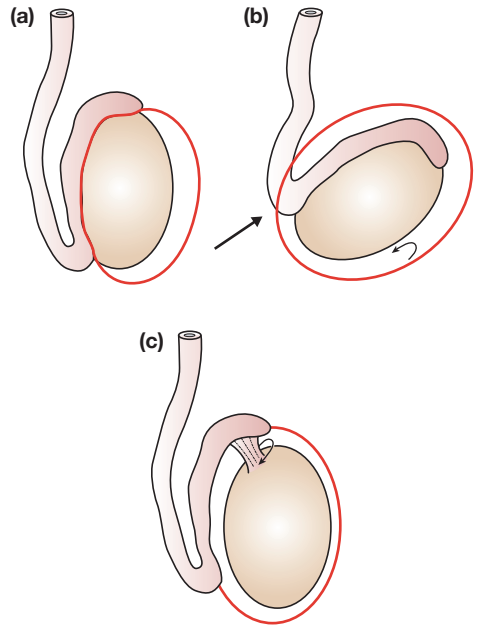

Figure 86.4 Testicular torsion. **(a)** Normal attachment. **(b)** An abnormally high attachment (arrow) of the tunica vaginalis predisposes to torsion – the 'bell-clapper'. **(c)** Separation of the testis from the epididymis – torsion about the pedicle between them.

The two main factors determining damage to the testis are the extent of the twist and the duration of the episode. Twists of 720° cause more rapid ischaemia than twists of 360° or less, and if the testis can be untwisted within 6 hours of the torsion taking place there is nearly a 100% chance of testicular salvage compared with a 20% salvage rate if the surgery is delayed for 24 hours.

Occasionally the testis untwists spontaneously without surgical treatment and 'intermittent' testicular torsion should be considered as a cause of testicular pain in adolescents.

Clinical features

Testicular torsion is most common between 10 and 25 years of age, although a few cases occur outside this age range. Typically there is sudden severe pain in the groin and the lower abdomen and the patient feels nauseated and may vomit. The scrotum is swollen and tender, while the skin is usually not erythematous initially (although it may become so with a prolonged history) and the patient is apyrexial. The testis itself is swollen and tender and seems high within the scrotum, while the tender twisted cord can often be palpated above it. The cremasteric reflex is lost.

Differential diagnosis

Skin redness and mild pyrexia may result in the condition being confused with epididymo-orchitis in the older patient; however,

Figure 86.5 Idiopathic oedema of the scrotum.

there will usually be dysuria associated with an accompanying urinary infection. Elevation of the testis reduces the pain in epididymo-orchitis but makes it worse in torsion.

Torsion of a testicular appendage cannot always be distinguished with certainty from testicular torsion. The most common structure to twist is the appendix of the testis (the hydatid of Morgagni), which is sometimes visible through the scrotal wall as a small dark spot. If the diagnosis is made clinically, conservative management is possible; if in doubt, surgical exploration should be undertaken with removal of the twisted appendage.

In mumps orchitis, the cord is not particularly thickened and the condition is often bilateral.

Idiopathic scrotal oedema is an oddity that occurs between the age of 4 and 12 years and must be differentiated from torsion. The scrotum is very swollen but there is little pain or tenderness. The swelling is usually bilateral and may extend into the perineum, groin and penis. It is thought to be an allergic phenomenon and occasionally there is eosinophilia. The swelling subsides after a day or so but may recur (*Figure 86.5*).

Very occasionally, torsion can be convincingly mimicked by a small tense strangulated inguinal hernia compressing the cord and causing compression of the pampiniform plexus.

Management

The management of the case should be determined primarily on clinical grounds. While Doppler ultrasound scanning (*Figure 86.6*) can confirm the absence of the blood supply to the affected testis, false-positive results can be seen so it is not routinely recommended. If there is any doubt as to the diagnosis, then urgent scrotal exploration is indicated. The typical window of opportunity for surgical intervention and testicular salvage is 6 hours from onset of pain. Therefore, early urological surgery consultation upon presentation may be critical even in the absence of confirmatory testing.

Exploration for torsion can be performed through a transverse or midline scrotal incision. If the testis is viable when the cord is untwisted, it should be prevented from twisting again by fixation with three non-absorbable sutures between the tunica albuginea of the testis and the scrotal raphe. The use of absorbable sutures risks the possibility of recurrent torsion at some time in the future. The other testis should also be fixed because the anatomical predisposition is likely to be bilateral. If there is clinical doubt as to testicular viability after detorsion of the testis, then it should be wrapped in a warm swab and observed over a few minutes. If a small incision in the tunica albuginea demonstrates bright red arterial bleeding then the testis may survive. An infarcted testis should be removed – the patient can be counselled later about a prosthetic replacement.

In cases where there is a history of pain for several days, the affected testis will be dead. It is not possible to recover such a testis and, although little is gained (other than pain relief) by immediate exploration, it is necessary to fix the contralateral testis.

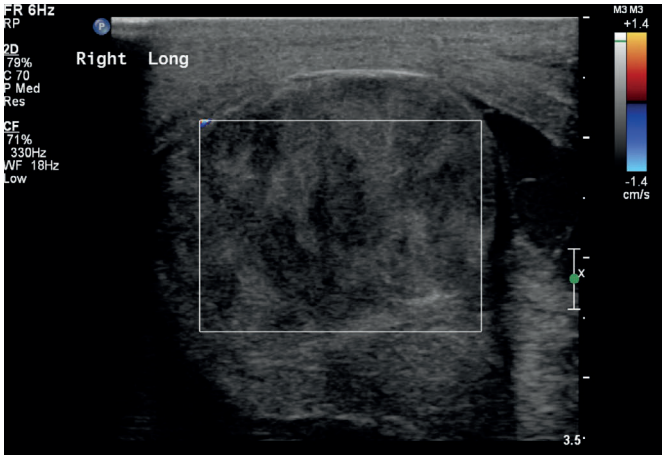

Figure 86.6 Doppler ultrasound scanning of a torted right testis showing the absence of blood flow and heterogeneous architecture indicating late necrosis (courtesy of Dr Davide Prezzi).

Summary box 86.3

Testicular torsion

- If the diagnosis of testicular torsion is possible, then surgical exploration is indicated
- Prompt exploration, untwisting and fixation is the only way to save the torted testis
- The patient should be counselled and consented for orchidectomy before exploration
- The anatomical abnormality is bilateral and the contralateral testis should also be fixed
- Non-absorbable sutures should be used for the fixation of each testis

Giovanni Battista Morgagni, 1682–1771, Professor of Anatomy, University of Padua, Padua, Italy, is associated with a number of eponymous structures, including the aortic sinus, the appendix testis, the anal columns and the sternocostal triangles. He is regarded as the 'father of morbid anatomy'.
Christian Johann Doppler, 1803–1853, Professor of Experimental Physics, Vienna, Austria, enunciated the 'Doppler principle' in 1842.

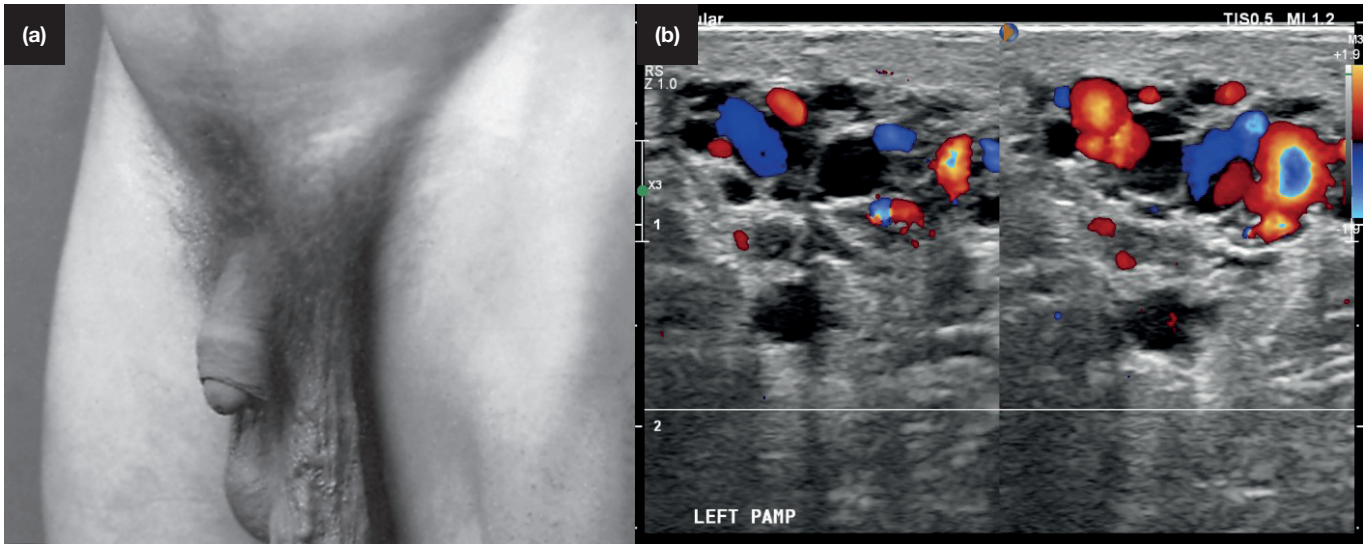

Figure 86.7 (a) Large varicocele in a pendulous scrotum. Note the left inguinal hernia. **(b)** Doppler ultrasound of a left varicocele (courtesy of Dr Davide Prezzi).

VARICOCELE

Definition

A varicocele is an abnormal dilatation and enlargement of the scrotal venous plexus draining the testis.

Incidence

Varicoceles are common, affecting 10–20% of adult males. About 90% are left sided, reflecting the proximal venous anatomy – the left testicular vein empties into the relatively high-pressure left renal vein while the right empties into the low-pressure inferior vena cava below the right renal vein. If a left varicocele is identified, there is a 30–40% probability that it is a bilateral condition.

They are unusual in boys and typically develop during late childhood and adolescence. Varicoceles occur in around 15–20% of all males but are found in about 40% of infertile males.

Pathophysiology

The veins draining the testis and the epididymis form the pampiniform plexus. The veins gradually join each other as they traverse the inguinal canal and at, or near, the inguinal ring there are only one or two testicular veins, which pass upwards within the retroperitoneum. The left testicular vein empties into the left renal vein while the right empties into the inferior vena cava below the right renal vein. There is an alternative (collateral) venous return from the testes through the cremasteric veins, which drain mainly into the inferior epigastric veins.

There are three theories as to the cause of varicoceles:

1. The absence or failure of the antireflux valve usually located where the testicular vein joins the left renal vein or the inferior vena cava on the right. This causes reflux and retrograde flow in the testicular vein.
2. The 'nutcracker' effect that occurs when the left testicular vein gets trapped between the superior mesenteric artery and the aorta. This causes venous compression and testicular vein obstruction.
3. Angulation at the junction of the left testicular vein and the left renal vein.

In some cases, the dilated vessels are cremasteric veins and not part of the pampiniform plexus. While most varicoceles are idiopathic, obstruction of the testicular vein by a renal tumour or nephrectomy is a cause of varicocele in later life; characteristically, in such cases the varicocele does not decompress in the supine position. The presence of an isolated right-sided varicocele is extremely rare. Hence, imaging should be considered to exclude a retroperitoneal mass in such cases. Rarer causes include deep vein thrombosis, renal arteriovenous malformations and thrombosis of the pampiniform plexus.

Clinical features

While most varicoceles are asymptomatic, those that are symptomatic tend to present in adolescence or early adulthood, when there may be a dragging discomfort that is worse on standing at the end of the day. When examined in the erect position, the scrotum on the affected side often hangs lower than normal (***Figure 86.7a***); on palpation, with the patient standing, the varicose plexus feels like a bag of worms. There may be a cough impulse. If the patient lies down the veins empty by gravity and this provides an opportunity to ensure that the underlying testis is normal to palpation. In longstanding cases the affected testis is smaller and softer than the opposite side owing to atrophy.

Ultrasound can be helpful in the diagnosis of small varicoceles (***Figure 86.7b***), and in the less common right/bilateral varicoceles (and older men with an apparently recent onset of

varicocele), ultrasound of the kidneys is important in excluding a renal tumour.

The following classification of varicocele is useful in clinical practice:

- subclinical: not palpable or visible at rest or during a Valsalva manoeuvre, but can be shown by special tests (Doppler ultrasound studies);
- grade 1: palpable during Valsalva manoeuvre, but not otherwise;
- grade 2: palpable at rest, but not visible;
- grade 3: visible and palpable at rest.

Varicoceles and infertility

Varicoceles are present in 10–20% of adult men and in over 25% of men with abnormal semen analysis. The exact association between reduced male fertility and varicocele is unknown. The most accepted theory is that increased blood flow leads to higher intratesticular temperatures, which are the main cause of impaired sperm in varicoceles.

Large varicoceles may eventually cause testicular failure, ultimately resulting possibly in lower testosterone production, low sperm count and quality and testicular atrophy. Varicoceles can also decrease sperm nuclear DNA integrity, which has been linked to poor sperm motility, viability, counts and morphology.

A Cochrane review from 2012 concluded that there is some evidence to suggest that treatment of a varicocele in men from couples with otherwise unexplained subfertility may improve a couple's chance of spontaneous pregnancies. However, varicocele repair in men with a subclinical varicocele or normal semen parameters is considered ineffective for increasing the chances of spontaneous pregnancies. Varicocelectomy may also improve outcomes following assisted reproductive techniques in men with abnormal sperm parameters.

Treatment

Varicocele repair can be effective in men with a low sperm count, a clinical varicocele and otherwise unexplained infertility. However, treatment of varicocele in adolescents poses a risk of overtreatment: most boys with a varicocele will have no fertility problems later in life.

When the discomfort is significant, then percutaneous embolisation of the gonadal veins is the usual first-line intervention. If this is not possible, or if the varicocele recurs (as it does in around 20% after embolisation), surgical ligation of the testicular veins is the appropriate treatment, although recurrence can occur even after such surgery. Current evidence indicates that microsurgical varicocelectomy is the most effective method among the different surgical varicocelectomy techniques, with fewer complications and lower recurrence rates.

Summary box 86.4

Varicocele

- Varicocele is a common condition and 90% are left sided
- The presence of varicocele in some men is associated with progressive testicular damage from adolescence onwards and a consequent reduction in fertility
- Varicocele repair can be effective in men with a low sperm count, a clinical varicocele and otherwise unexplained infertility

HYDROCELE

Definition

A hydrocele is an abnormal collection of serous fluid in a part of the processus vaginalis, usually the tunica vaginalis around the testis and occasionally along the spermatic cord. Acquired hydroceles are primary or idiopathic, or secondary to epididymal or testicular disease.

Incidence

Hydroceles affect an estimated 1% of adult men. More than 80% of newborn boys have a patent processus vaginalis, but most close spontaneously within 18 months of age.

Pathophysiology

Embryologically, the processus vaginalis is a diverticulum of the peritoneal cavity. It descends with the testes into the scrotum via the inguinal canal around the 28th week of gestation with gradual closure through infancy and childhood.

Structurally, hydroceles are classified into three key types:

1. Communicating (congenital) hydrocele: a patent processus vaginalis permits flow of peritoneal fluid into the scrotum (tunica vaginalis); associated with indirect inguinal hernias (***Figure 86.8a***).
2. Non-communicating (vaginal) hydrocele: the processus vaginalis is closed with no communication with the peritoneal cavity. Instead, fluid accumulation can be due to excessive production and/or defective absorption by the tunica vaginalis, primarily because of disruption to the lymphatic drainage of scrotal structures (***Figure 86.8b***). If idiopathic, these are called 'primary' hydroceles.
3. The distal end of the processus vaginalis closes correctly, but the mid-portion of the processus remains patent. The proximal end may be open and communicating with the tunica vaginalis, resulting in an 'infantile' hydrocele' (***Figure 86.8c***), or closed, resulting in a hydrocele of the cord (***Figure 86.8d***).

Non-communicating primary hydroceles are the most common type of hydrocele globally. 'Secondary' hydroceles usually occur in men >40 years and may present acutely from local injury (including torsion), infection, neoplasm or radiotherapy. If a tumour is suspected, the hydrocele should not be punctured (risk of malignant needle-track implantation).

Antonio Maria Valsalva, 1666–1723, Italian physician and anatomist.

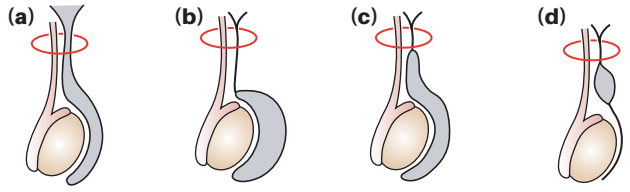

Figure 86.8 (a) Vaginal hydrocele (very common); **(b)** 'infantile' hydrocele; **(c)** congenital hydrocele; **(d)** hydrocele of the cord.

Clinical features

Examination of a scrotal swelling should be undertaken in both the upright and supine position. The examiner should ask:

1. Is it possible to get above the swelling to palpate a normal cord? If not the swelling may represent an inguinal hernia that has entered the scrotum.
2. Is the testicle or epididymis palpable or is the swelling enclosing both of those structures? A hydrocele encloses the testis and epididymis such that they may be impalpable, and it is possible to get 'above' it to palpate a normal spermatic cord.
3. Does the swelling transilluminate? Hydroceles are typically translucent.

In almost all cases of scrotal swelling an ultrasound is a useful adjunct to clarify the nature of the swelling and assess whether the testis itself is diseased.

A primary hydrocele (***Figure 86.9***) is seen most commonly in middle and later life, but can also occur in older children. Because the swelling is usually painless it may reach a significant size before the patient presents for treatment. Be wary of an acute hydrocele in a young man since there may be a testicular tumour.

In congenital hydrocele, the processus vaginalis – the communication with the peritoneal cavity – is usually too small to allow herniation of intra-abdominal contents. Pressure on the hydrocele does not always empty it but the hydrocele fluid may drain into the peritoneal cavity when the child is lying down; thus, the hydrocele may be intermittent. Ascites should be checked for if the swellings are bilateral.

A hydrocele of the cord is a smooth oval swelling that lies above the testis near the spermatic cord, which is liable to be mistaken for an inguinal hernia. The swelling moves downwards and becomes less mobile if the testis is pulled gently downwards. Hydrocele of the canal of Nuck is a similar condition in females. The cyst lies in relation to the round ligament and is always at least partially within the inguinal canal.

Treatment

Congenital hydroceles are treated by ligation of the patent processus vaginalis (herniotomy) if they do not resolve spontaneously.

Small hydroceles do not need treatment. If they are sizeable and bothersome for the patient, then surgical treatment is indicated. Established acquired hydroceles often have thick walls. There are three main surgical techniques for hydroceles:

1. **Plication**. Lord's operation is suitable when the sac is reasonably thin walled (***Figure 86.10***). There is minimal dissection and the risk of haematoma is reduced.
2. **Eversion**. The sac is opened and everted behind the testis, with placement of the testis in a pouch prepared by dissection in the fascial planes of the scrotum (Jaboulay's procedure) (***Figure 86.10***).

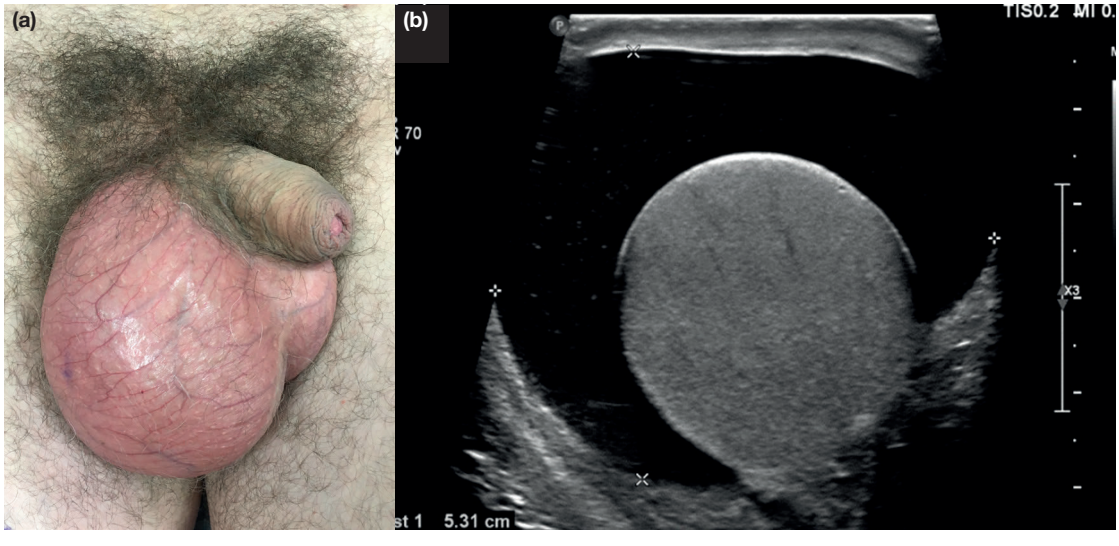

Figure 86.9 A right-sided hydrocele **(a)**. Ultrasound image **(b)** (courtesy of Dr Davide Prezzi).

Anton Nuck, 1650–1692, Professor of Anatomy and Medicine, Leiden, The Netherlands.
Peter Herent Lord, contemporary, formerly surgeon, Wycombe General Hospital, High Wycombe, UK.
Mathieu Jaboulay, 1860–1913, Professor of Surgery, Lyons, France.

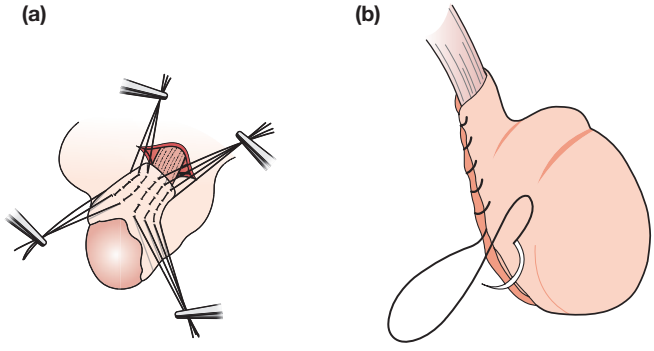

Figure 86.10 Lord's operation **(a)**. A series of interrupted absorbable sutures is used to plicate the redundant tunica vaginalis. When these are tied, the tunica bunches at its attachment to the testis. Jaboulay's procedure **(b)**. The hydrocele sac is everted and anchored with sutures. Unless great care is taken to stop bleeding after excision of the wall, haemorrhage from the cut edge is liable to cause a large scrotal haematoma. Overrunning stitches at the cut edge can be used to reduce this risk.

3 **Aspiration** of the hydrocele fluid is simple, but the fluid always reaccumulates within a week or so. It may be suitable for men who are unfit for scrotal surgery, although hydrocele surgery can be undertaken under local anaesthetic. Aspiration can result in bleeding into the hydrocele sac and haematocele formation. Injection of a sclerosant, such as tetracycline, can be effective but painful.

Summary box 86.5

Hydrocele

- A hydrocele is a collection of fluid within the tunica vaginalis
- Hydroceles surround the testis and transilluminate brightly
- Ultrasound examination is valuable, especially when the testis and epididymis are impalpable
- Hydroceles can be treated conservatively unless they are large and symptomatic
- Surgery is the mainstay of treatment
- Testicular malignancy is an uncommon cause of hydrocele that can be excluded by ultrasound examination

Filarial hydroceles and chyloceles

Filarial hydroceles and chyloceles account for up to 80% of hydroceles in tropical countries, where the parasite *Wuchereria bancrofti* is endemic. Filarial hydroceles follow repeated attacks of filarial epididymo-orchitis. Occasionally, the fluid contains liquid fat, which is rich in cholesterol. This is caused by rupture of a lymphatic varix with discharge of chyle into the hydrocele. In longstanding chyloceles, there are dense adhesions between the scrotum and its contents. Filarial elephantiasis supervenes in a small number of cases. Treatment is by rest and aspiration with chronic cases treated by excision of the sac.

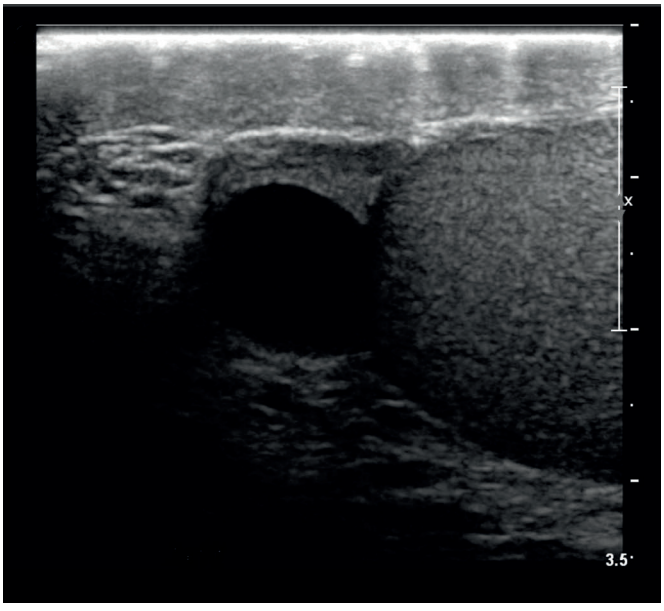

Figure 86.11 Ultrasound image of an epididymal cyst (courtesy of Dr Davide Prezzi).

CYSTS ASSOCIATED WITH THE EPIDIDYMIS

There are several types of cyst associated with the epididymis, including epididymal cysts and spermatoceles.

Epididymal cysts

These are filled with a clear fluid. They are very common, usually multiple and vary in size at presentation. They represent cystic degeneration of the epididymis. Cysts of the epididymis are usually found in middle age and are often bilateral. The clusters of tense cysts feel like tiny bunches of grapes that lie posterior to, and quite separate from, the testis. They should transilluminate. The diagnosis can by confirmed by ultrasound (***Figure 86.11***).

Aspiration is ineffective because the cysts are usually multilocular. If they are causing discomfort they should be excised. While single large cysts can be excised separately, recurrent or multilocular cysts usually require partial or total epididymectomy. Excision should be expected to interfere with the transportation of sperm from the testis on that side and young men should be counselled regarding this.

Spermatocele

This is a unilocular retention cyst derived from a portion of the sperm-conducting mechanism of the epididymis. A spermatocele typically lies in the epididymal head above and behind the upper pole of the testis. It is usually softer and laxer than other cystic lesions in the scrotum but, like them, it transilluminates. The fluid contains spermatozoa and resembles barley water in

Otto Eduard Heinrich Wucherer, 1820–1873, German physician who practised in Brazil.
Joseph Bancroft, 1836–1894, English physician working in Australia.

appearance. Spermatoceles are usually small. Small spermatoceles can be ignored. Larger ones can be excised.

Summary box 86.6

Cysts associated with the epididymis

- Lie posterior to and separate from the testis and they transilluminate
- Diagnosis can be confirmed by ultrasound examination
- Can be treated conservatively unless they are large or uncomfortable

INFECTIONS OF THE TESTIS AND EPIDIDYMIS

Epididymo-orchitis

Definition

Inflammation confined to the epididymis is epididymitis; if this inflammation, usually due to infection, involves the testis it is called epididymo-orchitis.

Incidence

Epididymitis, commonly preceding epididymo-orchitis, occurs in about 1 in 1000 men annually. Acute epididymitis most commonly occurs in men aged 20–59 years (43% in men aged 20–39 years and 29% in men aged 40–59 years). Childhood (prepubertal) epididymitis is rare; torsion is more common in this age group. Forty-seven per cent of prepubertal boys with epididymitis have associated urogenital abnormalities, including ectopic vas deferens or ureters, and urethral abnormalities.

Pathophysiology

Infection reaches the epididymis via the vas from a primary infection of the urethra, prostate or seminal vesicles. A general rule is that epididymitis arises in sexually active young men from a sexually transmitted genital infection, while in older men it more usually arises from a urinary infection or may be secondary to an indwelling urethral catheter.

In young sexually active men, the most common cause of epididymitis is now *Chlamydia trachomatis*, but gonococcal epididymitis is still occasionally seen. In older men with bladder outflow obstruction, epididymitis may result from a urinary infection – it is proposed that a high pressure in the prostatic urethra might cause reflux of infected urine up the vasa. Blood-borne infections of the epididymis are less common but may be suspected when there is epididymal infection without evidence of urinary infection; it is presumably the only possible mechanism in men who have previously undergone a vasectomy. Acute epididymo-orchitis can follow any form of urethral instrumentation and it is particularly common when an indwelling catheter is associated with infection of the prostate.

Infection usually starts in the tail of the epididymis and spreads to the rest of the epididymis and occasionally to the testis. Complications include abscess formation, testicular infarction, testicular atrophy, chronic induration and inflammation and infertility.

Clinical features

While there may be initial symptoms of a urinary or a genital infection, such symptoms are not always seen. The development of an ache in the groin and a fever can herald the onset of epididymitis. The epididymis and testis swell and become painful. The scrotal wall, at first red, oedematous and shiny, may become adherent to the epididymis.

Investigation should include a urethral swab, a urine specimen for culture, nucleic acid amplification testing (NAAT) of either a urine specimen or a urethral swab and scrotal ultrasound. Urinalysis will usually show leukocytes and may show a formal urinary tract infection. NAAT is a sensitive way of identifying both gonococcal and chlamydial urethritis. Ultrasound is useful in the initial assessment of epididymitis (***Figure 86.12***) and will identify abscess formation.

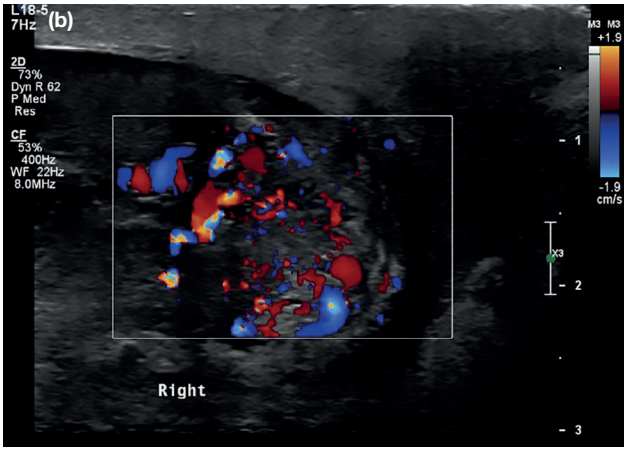

Figure 86.12 Ultrasound findings in epididymitis. Enlarged epididymis with a heterogeneous echotexture (grey-scale ultrasonography) **(a)** and increased blood flow (Doppler ultrasonography) **(b)** (courtesy of Dr Davide Prezzi).

In adolescents, the differential diagnosis is testicular torsion; if there is any clinical doubt as to the diagnosis then testicular exploration should always be performed.

Treatment

To prevent complications and transmission of sexually transmitted infections, presumptive therapy is indicated at the time of the visit before all laboratory test results are available.

Presumptive therapy is based on risk for chlamydia and gonorrhoea (usually younger men) and/or gut organisms (usually older men). The aims of treatment of acute epididymitis are (i) cure of infection, (ii) improvement of signs and symptoms, (iii) prevention of transmission of chlamydia and gonorrhoea to others, and (iv) a decrease in potential epididymitis complications (e.g. infertility and chronic pain). Local sensitivities do change with increasing antibiotic resistance. Examples of regimens are shown below from the 2021 Sexually Transmitted Infections Treatment Guidelines from the US Centers for Disease Control and Prevention (https://www.cdc.gov/std/treatment-guidelines/STI-Guidelines-2021.pdf).

- For acute epididymitis most likely caused by sexually transmitted chlamydia and gonorrhoea:
  - Ceftriaxone intramuscularly (IM) single dose and oral doxycycline for 10 days.
- For acute epididymitis most likely caused by sexually transmitted and enteric organisms (men who practise insertive anal sex):
  - Ceftriaxone IM single dose and levofloxacin for 10 days.
- For acute epididymitis most likely caused by enteric organisms:
  - Levofloxacin for 10 days.
- There should be contact tracing of the partner and treatment if necessary.

In older men, quinolones are the usual initial treatment; however, if there is evidence of systemic sepsis, intravenous antibiotics may be valuable. If an organism is isolated from the urine, this simplifies the choice of antibiotic.

Local measures including scrotal support and analgesia are helpful. Oral antibiotic treatment should continue for at least 10 days or until the inflammation has subsided. If abscess formation occurs, drainage is necessary.

Chronic disease

Chronic non-tuberculous epididymitis usually follows the failure of resolution of an acute episode of epididymitis. Patients typically complain of intermittent episodes of discomfort and the epididymis feels thickened and tender. Treatment involves use of antibiotics (usually quinolones or doxycycline) and anti-inflammatory agents for 4–6 weeks. Epididymectomy or orchidectomy can be considered if there is no resolution, although up to 50% of patients continue to have pain despite such surgery.

Summary box 86.7

Acute epididymo-orchitis

- In young men usually arises secondary to a sexually transmitted genital infection
- In older men usually arises secondary to urinary infection
- May be a complication of catheterisation or instrumentation of the urinary tract
- May need aggressive treatment with parenteral antibiotics

Tuberculous epididymo-orchitis

Chronic tuberculous epididymo-orchitis usually begins insidiously. The frequency with which the lower pole of the epididymis is involved first indicates that the infection is usually retrograde from a tuberculous focus in the seminal vesicles.

Clinical features

Typically, there is a firm, uncomfortable discrete swelling of the lower pole of the epididymis. The disease progresses until the whole epididymis is firm and craggy behind a normal-feeling testis. There is a lax secondary hydrocele in 30% of cases, and a characteristic beading of the vas may be apparent as a result of subepithelial tubercles. The seminal vesicles feel indurated and swollen. In neglected cases, a tuberculous 'cold' abscess forms, which may discharge. The body of the testis may be uninvolved for years but the contralateral epididymis often becomes diseased. In two-thirds of cases there is evidence of renal tuberculosis or previous disease. Otherwise, patients typically appear healthy.

The urine and semen should be examined repeatedly for tubercle bacilli in all patients with chronic epididymo-orchitis. Imaging of the chest and upper urinary tract should be performed. Ultrasound will demonstrate a thickened epididymis.

Treatment

Secondary tuberculous epididymitis may resolve when the primary focus is treated. Treatment with antituberculous drugs is less effective in genital tuberculosis than in urinary tuberculosis. If resolution does not occur within 2 months, epididymectomy or orchidectomy is advisable. A course of antituberculous chemotherapy should be completed even if there is no evidence of disease elsewhere.

Other common forms of orchitis

Mumps orchitis, which is the most common form of orchitis, develops in 20–30% of postpubertal patients with a mumps virus infection and it usually develops as the parotid swelling is waning. Evidence of immunoglobulin M antibodies in the serum supports the diagnosis. The main complication is testicular atrophy, which may cause infertility if the condition is bilateral. Partial testicular atrophy is associated with persistent testicular pain.

Syphilitic orchitis is now uncommon. It can cause bilateral orchitis (which is a feature of congenital syphilis), interstitial fibrosis (which causes painless destruction of the testis) or, rarely, a gumma of the testis (which presents as a unilateral slowly growing painless swelling). The last presentation may be difficult to distinguish from a neoplasm without surgical exploration. Diagnosis is confirmed by serology.

TUMOURS OF THE TESTES

Incidence

Testicular cancer represents around 1–1.5% of male neoplasms and there is clear evidence of an increased incidence of these tumours in the past 30 years with 3–10 new cases per 100 000 males/per year in western societies. The predominant histology is germ cell tumours (GCTs) (90–95% of cases). The peak incidence of seminomas is in the fourth decade of life, with the non-seminomatous germ cell tumours (NSGCT) being more common in the third decade of life. They are the commonest form of tumour in young men. A specific genetic marker – an isochromosome of the short arm of chromosome 12 (i12p) – is pathognomonic of all types of adult GCTs as well as germ cell neoplasia *in situ* (GCNIS). Epidemiological risk factors include cryptorchidism, male factor infertility (including Klinefelter syndrome), familial history of testicular tumours among first-grade relatives and the presence of a contralateral tumour or GCNIS.

Classification and pathology

Tumours of the testis are classified according to their predominant cellular type:

- **GCTs** (90–95%): these include seminoma, embryonal cell carcinoma, yolk sac tumour, teratoma and choriocarcinoma;
- **sex cord–stromal tumours** (1–2%): these include Leydig cell tumours;
- **lymphoma** (3–7%);
- **other tumours** (1–2%).

Seminoma

A seminoma typically has a cut surface that is homogeneous and pinkish cream in colour. It appears to compress neighbouring testicular tissue (***Figure 86.13***). It consists of oval cells with clear cytoplasm and large, rounded nuclei with prominent acidophilic nucleoli. Sheets of cells resembling spermatocytes are separated by a fine fibrous stroma. Active lymphocytic infiltration of the tumour suggests a good host response and a better prognosis. Seminoma accounts for 50% of all testicular germinal cell tumours. They seldom occur in childhood, in young adults or in patients over 70 years of age.

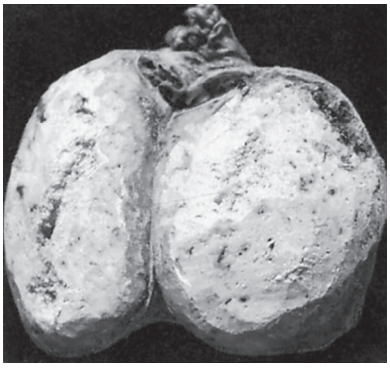

Figure 86.13 Seminoma of the testis.

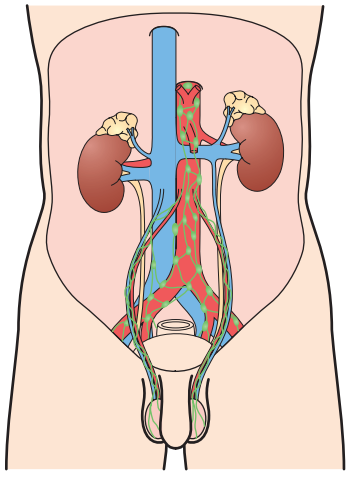

Figure 86.14 Lymphatic drainage of the testes to para-aortic lymph nodes.

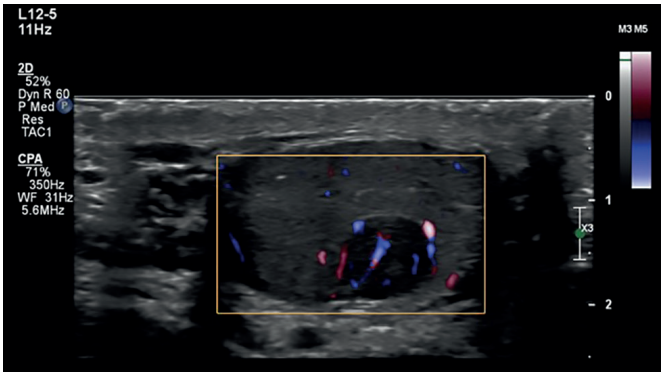

Figure 86.15 Ultrasound of a small seminoma with minimal distortion of the tunica albuginea (courtesy of Dr Davide Prezzi).

Seminomas metastasise mainly via the lymphatics (***Figure 86.14***) and haematogenous spread is uncommon. The lymphatic drainage of the testes is to the para-aortic lymph nodes near the origin of the gonadal vessels. The contralateral para-aortic lymph nodes are sometimes involved by tumour spread, but the inguinal lymph nodes are affected only if the scrotal skin is involved. Ultrasound is the first-line investigation (***Figure 86.15***).

Non-seminomatous germ cell tumours

There are a number of histological types of NSGCT, which may coexist within a single tumour:

- **Embryonal carcinoma** (***Figure 86.16***). Highly malignant tumours that occasionally invade cord structures.
- **Yolk sac tumour**. Usually present with a loose stroma and a component similar to embryonal carcinoma, sometimes with liver and intestinal tissue differentiation. It appears as a single tumour type in children and part of a

Harry Fitch Klinefelter Jr, 1912–1990, physician of Baltimore, MD, USA, described this syndrome in 1942.

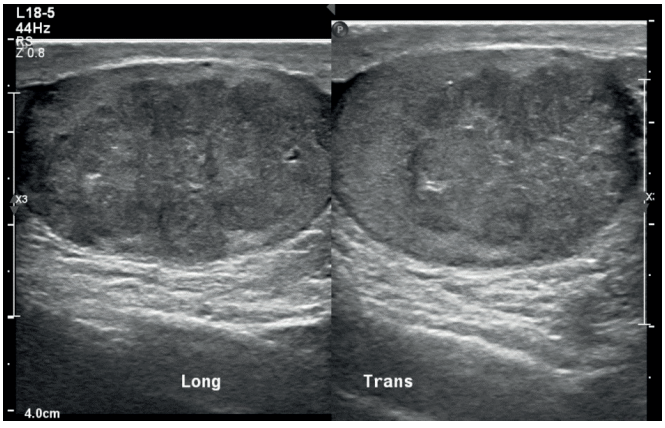

Figure 86.16 Ultrasound of a large embryonal carcinoma occupying nearly the whole testis; long, longitudinal view; trans, transverse view (courtesy of Dr Davide Prezzi).

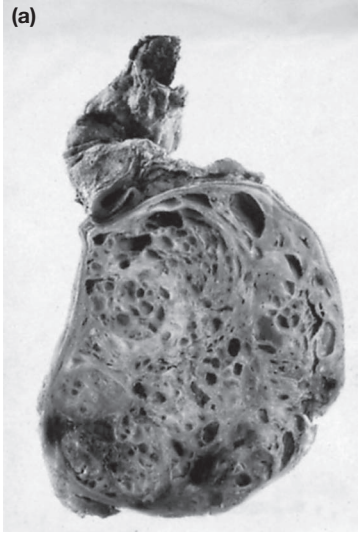

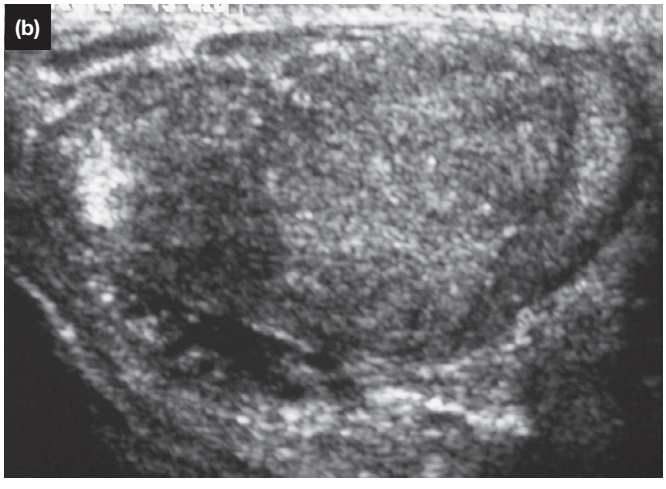

Figure 86.17 Teratoma of the testis specimen (a). Note the solid and cystic areas (courtesy of Dr Keith Simpson, London, UK). Testicular ultrasound (b). The homogeneous tissue of the testicular teratoma on the left of the image produces multiple ultrasound reflections.

mixed tumour in adults. They produce alpha-fetoprotein (AFP), which can be measured in serum.

- **Teratoma** (*Figure 86.17*). Teratomas consist of different tissues derived from ectoderm, endoderm and mesoderm. Immature components are often neuroectodermal or mesenchymal tissue, while more mature tissue is often cystic with epithelial differentiation or consists of smooth muscle, connective tissue or cartilage. Since most teratomas consist of a mixture of tissues, the old separation into mature and immature types has been abandoned. All can metastasise.
- **Choriocarcinoma**. This is part of a testicular GCT in 25% of tumours in adults. It very seldom appears as the single tumour component. Choriocarcinoma is almost never seen in childhood. This tumour produces human chorionic gonadotropin (HCG), which can be detected in blood. This is a highly malignant tumour that metastasises early via both the lymphatics and the bloodstream.

Spermatocytic seminoma

This tumour was earlier believed to be a variant of seminoma, but is now considered to be a separate tumour type, accounting for 1–2% of all GCTs of the testis. Only seen in adult men usually >50 years old, they rarely metastasise; therefore, an orchidectomy is the only necessary treatment, even in large tumours. Development of sarcomas has been reported when left untreated for long time.

Sex cord–stromal tumours

Sex cord–stromal tumours are rare and constitute less than 5% of testicular neoplasms.

Leydig cell tumour

Leydig cell tumours are the most common type of sex cord–stromal tumours, constituting 1–3% of adult testicular tumours and 3% of testicular tumours in infants and children. These tumours occur in about 8% of patients with Klinefelter's syndrome. They are well delineated on histology and usually up to 5 cm in diameter. They are solid, yellow to tan in colour with haemorrhage and/or necrosis in 30% of cases. Most of these tumours are benign. Malignant transformation occurs in 10% and is related to increased size (>5 cm), increased cellular atypia, increased cell proliferation, necrosis, vessel invasion and DNA aneuploidy.

Sertoli cell tumour

Sertoli cell tumours account for less than 1% of testicular tumours, and the mean age at diagnosis is around 45 years, with sporadic cases under 20 years of age. Rarely, these occur in patients with androgen insensitivity syndrome and Peutz–Jeghers syndrome. The rate of malignancy ranges between 10% and 22%.

John Law Augustine Peutz, 1886–1968, Chief Specialist for Internal Medicine, St John's Hospital, The Hague, The Netherlands.
Harold Joseph Jeghers, 1904–1990, Professor of Internal Medicine, New Jersey College of Medicine and Dentistry, Jersey City, NJ, USA.

Granulosa cell tumour

Granulosa cell tumours of the testis are extremely rare in adult men, but a juvenile type accounts for 6% of testis tumours in childhood.

Mixed germ cell/sex cord tumour: gonadoblastoma

This tumour consists of two cell types: large germinal cell-like seminoma cells and small granulosa-like or Sertoli cells or rarely Leydig/luteinised cells. Gonadoblastoma is seen in individuals with mixed gonadal dysgenesis (risk 15–25%), which is associated with cryptorchidism, hypospadias, gynaecomastia or female internal genitalia. It seldom occurs in phenotypical and genotypical males.

Clinical features

Usually the patient presents with a painless testicular lump. A sensation of heaviness can occur if large, but few patients experience pain. Occasionally, an episode of trauma calls attention to the swelling. Some cases may simulate epididymo-orchitis and, rarely, acute painful enlargement of the testis occurs because of haemorrhage into the tumour, which can mimic testicular torsion.

Rarely, the predominant symptoms are those of metastatic disease. Intra-abdominal disease may cause abdominal or lumbar pain. Lung metastases are usually silent, but they can cause chest pain, dyspnoea and haemoptysis in the later stages of the disease. The primary tumour may not have been noticed by the patient, and indeed may be detected only by ultrasound (***Figure 86.15***).

On examination there is an intratesticular solid mass. A secondary hydrocele may be present. The epididymis can become more difficult to feel. Around 5% of cases have gynaecomastia (mainly NSGCT). Metastatic disease is rarely apparent clinically and is more usually identified by formal staging investigations. In 1–2% of cases the tumour is bilateral at diagnosis.

Investigation and staging

The diagnosis is confirmed by ultrasound scanning of the testis (***Figure 86.16***), which is also able to assess the contralateral testis. It is a mandatory test in all suspected cases of testicular tumour.

In confirmed cases, staging is an essential step in planning treatment. Blood is taken prior to orchidectomy to measure the levels of tumour markers, which are raised in around 50% of cases. A rise in AFP is seen in around 50–70% of NSGCTs and a rise in HCG is seen in 40–60% of NSGCTs and around 30% of seminomas. Lactate dehydrogenase (LDH) is expressed on chromosome 12p, which is often amplified in testis cancer cells. LDH is less specific for testis cancer than HCG or AFP. However, elevated LDH levels are associated with high tumour burden in seminoma and recurrence in NSGCT.

When raised, these markers are used to monitor the response to treatment. The mean serum half-lives of AFP and HCG are 5–7 days and 2–3 days, respectively, and reassessment of the markers following orchidectomy can indicate whether all the tumour tissue has been removed.

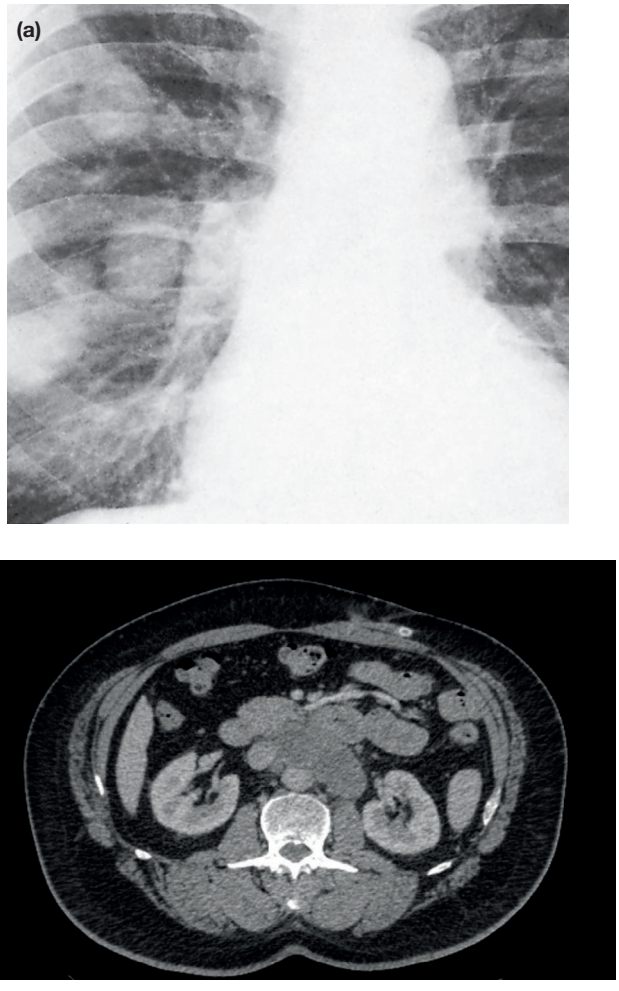

Figure 86.18 (a) Chest radiograph showing cannonball metastases from carcinoma of the testis and **(b)** computed tomography showing large para-aortic lymph node metastasis from carcinoma of the testis resulting in retroperitoneal mass (courtesy of Dr Davide Prezzi).

While a chest radiograph can show the 'classical' cannonball metastases (***Figure 86.18a***) CT scanning of the chest, abdomen and pelvis has taken over as the most useful means of detecting metastases and monitoring the response to therapy (***Figure 86.18b***).

Summary box 86.8

Testicular tumours

- A solid testicular lump that cannot be felt separately from the testis may be a malignant tumour
- Lymphatic spread is to the para-aortic lymph nodes
- Ultrasound is a mandatory investigation in all cases of suspected testicular tumour
- Tumour markers (AFP, HCG and LDH) should be measured prior to orchidectomy

Treatment

Men should be offered semen analysis and sperm banking prior to interventions such as surgery and chemotherapy that may render them infertile.

Surgery: radical orchidectomy

The orchidectomy is undertaken via an inguinal incision. The spermatic cord is displayed by dividing the external oblique aponeurosis and a soft clamp is placed across the cord to stop dissemination of malignant cells as the testis is mobilised into the wound. If there is a tumour the cord should be double transfixed and divided at the level of the internal inguinal ring and the testis removed.

Management by staging and histological diagnosis (after orchidectomy)

The treatment of patients with GCTs of the testis is usually successful, even in advanced cases. This largely reflects the excellent response of these tumours to chemotherapy and (for seminomatous tumours) to radiotherapy. Prognostic groups can be defined according to non-metastatic (stage I) and metastatic disease (lymph node metastasis – stage II; distant metastasis or nodal metastasis with elevated tumour markers – stage III). (The exact classification details can be found in the *TNM Classification of Malignant Tumours*, 8th edn; see ***Further reading***.) Between 75% and 80% of patients with seminoma and about 55–64% of patients with NSGCT have stage I disease at diagnosis.

The management strategies below are adapted from the European Association of Urology's current guidelines.

Non-metastatic disease (stage I)

Seminoma. About 15% of patients with clinical stage I (CSI) seminoma have subclinical metastatic disease, usually in the retroperitoneum, and will relapse after orchidectomy alone.

Surveillance. Recurrence rates of 6% have been described in patients with low-risk features, including tumours size <4 cm and no stromal rete testis invasion with cancer-specific survival rate reported with surveillance at >95%. The main limitation of surveillance is the need for intensive follow-up.

Adjuvant chemotherapy. One course of adjuvant carboplatin therapy compared with radiotherapy shows no significant difference in recurrence rate, time to recurrence and survival after a median follow-up of 4 years.

Adjuvant radiotherapy. Seminomas are radiosensitive. Radiotherapy to a para-aortic field or to para-aortic and ipsilateral iliac nodes reduces the relapse rate to 1–3%. The rate of severe radiation toxicity is <2%. The main concern is the long-term risk of secondary malignancies.

NSGCT. Up to 50% of patients with NSGCT with CSI disease have subclinical metastases and will relapse during surveillance.

- *Surveillance.* 14–48% of CSI-NSGCT patients undergoing surveillance have recurrence within 2 years of orchidectomy. Careful surveillance can be an option for compliant, risk-stratified (based on the presence of lymphovascular invasion) patients who are well informed about the expected recurrence rate as well as the salvage treatment.
- *Adjuvant chemotherapy.* One cycle of bleomycin–etoposide–cisplatin (BEP) is now the recommended strategy with recurrence rates of around 3%. The very long-term side effects, particularly cardiovascular, remain to be ascertained.
- *Retroperitoneal lymph node dissection (RPLND).* The role of this surgery has now decreased with 2-year recurrence-free survival with adjuvant BEP × 1 versus RPLND favouring chemotherapy with recurrence-free survival of 99.5% versus 91%.

Metastatic disease (stages II and III)

Treatment for metastatic testicular cancer is chemotherapy. Previously, radiotherapy was often used for early stage II seminoma but the cardiovascular and second malignancy risks have led to chemotherapy (three cycles of BEP or four cycles of etoposide and cisplatin [EP]) being the preferred alternative. Both are similarly effective, with a trend towards greater efficacy for chemotherapy in stage IIB seminoma. The initial treatment is chemotherapy (BEP) in all advanced cases of NSGCT except postpubertal teratoma without elevated tumour markers, which can be managed by RPLND surgery.

Sex cord–stromal tumours

Most of these tumours are benign (around 80%), so conservative treatment of small lesions with organ-sparing surgery is feasible, if the diagnosis is considered. For larger tumours, orchidectomy is necessary with multimodality treatment for those with the rare malignant forms of these tumours.

Summary box 86.9

Testis tumour staging and treatment

- Tumour markers (AFP, HCG and LDH) help to make the diagnosis and to follow the response to treatment
- CT scanning of chest, abdomen and pelvis is central to the staging of testicular tumours
- Testicular tumours are extremely sensitive to platinum-based chemotherapy
- Prognosis is excellent when the patient is treated with combination chemotherapy in a cancer centre

Testicular tumours in children

Paediatric testicular tumours are distinct from adult testicular tumours. GCTs in adults represent about 95% of all testicular tumours but only 60–75% in children. The most common malignant tumour in children is the yolk sac tumour, which is very rare in its pure form in adults. Surgical treatment usually begins with radical orchidectomy, which is often recommended whenever the AFP level is elevated (suggesting the presence of a yolk sac tumour at age >1 year). A normal AFP level in children suggests a strong likelihood of a benign tumour. For such tumours, as in cases of epidermoid cysts, testis-sparing surgery of the mass rather than radical orchidectomy can be considered.

TUMOURS OF THE EPIDIDYMIS

Paratesticular tumours are rare and account for about 5% of all intrascrotal tumours. Between 70% and 80% of all these tumours are benign and 30% of these occur in the epididymis. Epididymis tumours are commonly soft tissue or mesothelial neoplasm in origin. Benign cystadenomas, papillary tumours and adenomatoid tumours are the most common, although malignant sarcoma or secondary metastasis from a carcinoma may also occur. They are extremely rare.

THE SCROTUM

Fournier's gangrene

Fournier's gangrene is an uncommon and nasty condition (*Figure 86.19*) characterised by a polymicrobial infection of the soft tissues of the perineum, external genitalia and perianal region. It is a form of necrotising fasciitis. There is rapid onset of gangrene leading to exposure of the scrotal contents. Although it can occur in conjunction with sepsis of the testis, epididymis or perianal region, an obvious cause is absent in over half the cases. It can arise following minor injuries or procedures in the perineal area, such as a bruise, scratch, urethral dilatation, injection of haemorrhoids or opening of a periurethral abscess. Many patients have concurrent illnesses that diminish their defences, most notably diabetes mellitus and alcoholism.

There is a mixed infection of aerobic and anaerobic bacteria in a fulminating inflammation of the subcutaneous tissues, which results in an obliterative arteritis of the arterioles to the scrotal skin that in turn results in gangrene. The condition can spread rapidly to involve the fascia and skin of the penis, perineum and abdominal wall.

Figure 86.19 Fournier's gangrene with an area of necrotic skin overlying an area of scrotal inflammation.

Clinical features

The hallmark of Fournier's gangrene is intense pain and tenderness in the genitalia. The clinical course usually progresses through the following phases:

1. prodromal symptoms of fever and lethargy for 2–7 days;
2. intense genital pain usually associated with oedema of the overlying skin; pruritus may be present;
3. increasing genital pain with progressive erythema of the overlying skin;
4. dusky appearance of the overlying skin; subcutaneous crepitation;
5. obvious gangrene of part of the genitalia; purulent discharge from wounds.

Early on, pain may be out of proportion to the physical findings. As gangrene develops, pain may subside as nerve tissue becomes necrotic. Systemic effects of this process vary from local tenderness to massive septic shock, with the greater the necrosis the more severe the systemic effects.

Treatment

Treatment of a case of Fournier's gangrene is a surgical emergency. Initial management involves intravenous fluid resuscitation and broad-spectrum intravenous antibiotics. Urgent wide surgical excision of the dead and infected tissue is essential and the extent of the internal necrosis is typically much greater than the external appearances suggest, with extensive debridement often necessary. Urinary and faecal diversion may be necessary. Supportive care is essential because patients often become severely septic.

Early review of the wounds is helpful to confirm that all dead tissue has been removed; when the infection has been controlled, vacuum-assisted dressing is helpful, if it is available. If the patient survives the acute episode, skin grafting is often necessary. Despite best therapy, mortality rates as high as 50% are often reported.

Summary box 86.10

Fournier's gangrene

- Fournier's gangrene requires early and aggressive treatment if the patient is to survive
- Treatment involves urgent surgical debridement of necrotic tissue in combination with early use of intravenous broad-spectrum antibiotics

Jean Alfred Fournier, 1832–1915, syphilologist, founder of the Venereal and Dermatological Clinic, Hôpital St Louis, Paris, France.

Figure 86.20 Scrotal cancer.

Carcinoma of the scrotum

'Chimney sweep's cancer' was the first reported occupational cancer (described by Percival Pott in 1775). It is a rare cancer that has also been seen in other workers who come into contact with oil and coal products. Animal studies suggest that aromatic cyclic hydrocarbons are the aetiological factor. Nowadays, this tumour is rarely associated with any obvious aetiological factor.

The growth starts as a wart or ulcer (***Figure 86.20***); as it grows it may involve the testis. The tumour should be excised with a margin of healthy skin. The management of the inguinal nodes parallels the management of penile cancer, and nodal assessment, either with sentinel node biopsies or bilateral groin dissections, is indicated.

TRAUMA TO THE TESTIS

The testis can be damaged either by blunt or by penetrating trauma. Injuries can range from simple bruising, through significant intratesticular haematomas to rupture of the tunica albuginea, with very significant collections of blood within the tunica vaginalis (haematocele) (***Figure 86.21***). If the tunica ruptures, the blood can track into the groin and perineum.

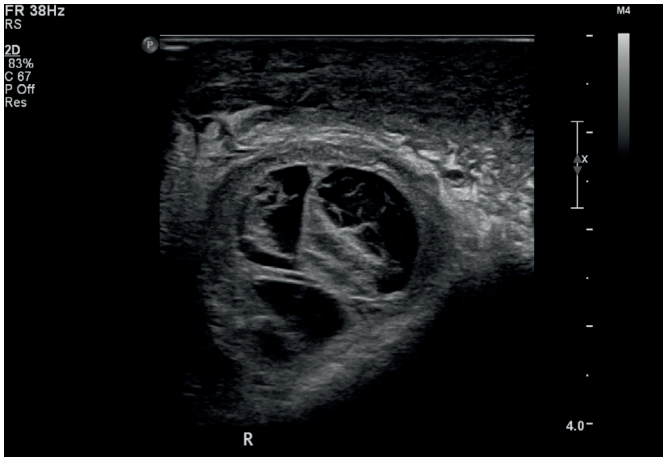

Figure 86.21 Ultrasound of a ruptured testicle with a haematocele (courtesy of Dr Davide Prezzi).

Careful clinical assessment, together with the use of ultrasound examination, is central to the management of men with a scrotal injury. Ultrasound has excellent sensitivity and specificity in the diagnosis of testicular rupture. If there is testicular rupture, there is good evidence that early surgical exploration, with debridement and repair of the tunica albuginea, is more likely to preserve useful testicular function. Also, early intervention results in orchidectomy in less than 10% compared with the 50% rate in delayed surgery.

Summary box 86.11

Scrotal trauma

- In cases of scrotal trauma, surgical exploration is indicated when there is testicular rupture or when there is a rapidly expanding scrotal haematoma
- Ultrasound is important in the assessment of the injury

FURTHER READING

Brierley JD, Gospodarowicz MK, Wittekind C (eds). *TNM classification of malignant tumours*, 8th edn. Oxford: Wiley Blackwell/Union for International Cancer Control, 2017.

Laguna MP, Albers P, Algaba F *et al. EAU guidelines on testicular cancer*. Arnhem, The Netherlands: EAU Guidelines Office, 2020. Available from https://uroweb.org/wp-content/uploads/EAU-Guidelines-on-Testicular-Cancer-2020.pdf.

Percival Pott, 1714–1788, surgeon, St Bartholomew's Hospital, London, UK, described chimney sweep's cancer of the scrotum in 1775. In those days the chimney sweep's apprentice climbed up inside the chimney.